

## Original Research Article

# IMMUNOHISTOCHEMICAL MARKERS IN HEPATOCELLULAR CARCINOMA: DIAGNOSTIC AND PROGNOSTIC IMPLICATIONS

Navdeep Singh<sup>1</sup>, Surendra Kumar<sup>2</sup>, Inam Danish Khan<sup>3</sup>

<sup>1</sup>Assistant Professor Department of Pathology, Army Hospital Research and referral, New Delhi, India.

<sup>2</sup>Assistant Professor, Department of Pathology, Command Hospital Air Force, Bangalore, India.

<sup>3</sup>Professor, Department of Microbiology, Army College of Medical Sciences, New Delhi, India.

Received : 05/05/2024  
Received in revised form : 02/07/2024  
Accepted : 17/07/2024

**Corresponding Author:**

**Dr. Navdeep Singh,**  
Assistant Professor Department of Pathology, Army Hospital Research and referral, New Delhi, India.  
Email: mann7057@gmail.com.

DOI: 10.70034/ijmedph.2024.3.17

Source of Support: Nil,  
Conflict of Interest: None declared

Int J Med Pub Health  
2024; 14 (3); 97-102

## ABSTRACT

**Background:** Hepatocellular carcinoma (HCC) is a leading cause of cancer-related mortality worldwide, necessitating improved diagnostic and prognostic markers. Immunohistochemical (IHC) markers such as alpha-fetoprotein (AFP), glypican-3 (GPC3), heat shock protein 70 (HSP70), and cytokeratin 19 (CK19) have shown promise in HCC detection and prognosis. However, their utility in clinical practice remains to be fully elucidated.

**Materials and Methods:** We conducted a retrospective study analyzing 129 HCC tissue samples for the expression of AFP, GPC3, HSP70, and CK19 using IHC staining. Clinicopathological parameters, including tumor size, grade, presence of cirrhosis, and patient survival, were correlated with marker expression. Survival analysis was performed using Kaplan-Meier curves and log-rank tests.

**Results:** Our analysis revealed variable expression patterns for AFP, GPC3, HSP70, and CK19 in HCC tissues. AFP and GPC3 exhibited moderate to high expression levels, while HSP70 showed moderate expression, and CK19 demonstrated lower expression. Positive correlations were observed between marker expression and tumor size, grade, and the presence of cirrhosis ( $p < 0.05$ ). Additionally, higher expression levels of AFP, GPC3, and HSP70 were associated with shorter overall survival and lower survival rates at 1 year and 3 years ( $p < 0.001$ ). In contrast, lower expression levels of CK19 were associated with better overall survival and higher survival rates.

**Conclusion:** Our study highlights the diagnostic and prognostic potential of AFP, GPC3, HSP70, and CK19 in HCC. These markers exhibit distinct expression patterns and associations with clinicopathological parameters and patient outcomes, underscoring their utility in guiding clinical management decisions. Further validation studies in larger cohorts are warranted to confirm our findings and facilitate the integration of these markers into routine clinical practice.

**Keywords:** Hepatocellular carcinoma, Immunohistochemistry, Alpha-fetoprotein, Glypican-3, Heat shock protein 70, Cytokeratin 19, Prognosis.

## INTRODUCTION

Global estimates suggest that HCC accounts for approximately 75-85% of primary liver cancers.<sup>[1]</sup> The incidence rates vary markedly across different regions, with the highest rates observed in Asia and Africa.<sup>[2,3]</sup> For instance, in regions where chronic hepatitis B virus (HBV) infection is endemic, such

as China and parts of Southeast Asia, HCC is particularly prevalent, constituting a significant portion of cancer-related morbidity and mortality. In contrast, in Western countries, where hepatitis C virus (HCV) infection and NAFLD are major risk factors, the incidence of HCC has been rising steadily over recent decades.<sup>[4,5]</sup>

Despite advances in treatment modalities, including surgical resection, liver transplantation, and targeted therapies, the prognosis for HCC remains poor, largely due to late-stage diagnosis and limited treatment options for advanced disease.<sup>[6]</sup> Therefore, there is an urgent need for reliable biomarkers that can aid in the early detection, prognosis, and therapeutic stratification of HCC.

Immunohistochemistry (IHC) has emerged as a valuable tool in the diagnosis and characterization of HCC.<sup>[7]</sup> By detecting specific protein markers expressed in tumor tissues, IHC enables the identification of HCC subtypes, assessment of tumor aggressiveness, and prediction of treatment response.<sup>[8]</sup> Several IHC markers, including alpha-fetoprotein (AFP), glypican-3 (GPC3), heat shock protein 70 (HSP70), and cytokeratin 19 (CK19), have shown promise as diagnostic and prognostic indicators in HCC.<sup>[9,10,11,12]</sup>

In this study, we aimed to evaluate the expression patterns of various IHC markers in HCC tissues and investigate their associations with clinicopathological features and patient outcomes. By elucidating the role of IHC markers in HCC pathogenesis and progression, our findings may contribute to the development of more effective diagnostic and therapeutic strategies for this deadly disease.

## MATERIAL AND METHODS

### Patient Cohort Selection

A comprehensive retrospective cohort of patients diagnosed with hepatocellular carcinoma (HCC) within a defined timeframe of 10 years from July 2013 to June 2023 was identified from the electronic medical records of department of Pathology at tertiary care center of North India. Inclusion criteria were strictly defined to ensure the homogeneity of the patient cohort. Patients with histologically confirmed HCC were included, and their clinical data, including demographic information, laboratory results, imaging findings, treatment history, and follow-up data, were carefully extracted. Exclusion criteria were rigorously applied to eliminate potential confounding factors. Patients with incomplete clinical data, inadequate tissue samples, or a history of other malignancies were excluded from the study cohort. So, a total of 129 patients diagnosed with hepatocellular carcinoma were enrolled in the study.

### Tissue Specimen Collection and Processing

A systematic approach was employed for the retrieval of formalin-fixed paraffin-embedded (FFPE) tumor tissue specimens from the pathology archives of the institution. Standard operating procedures (SOPs) were followed for the handling, labeling, and storage of tissue specimens to maintain sample integrity and traceability. Experienced histotechnologists prepared tissue sections of uniform thickness (4-5  $\mu\text{m}$ ) from FFPE blocks using

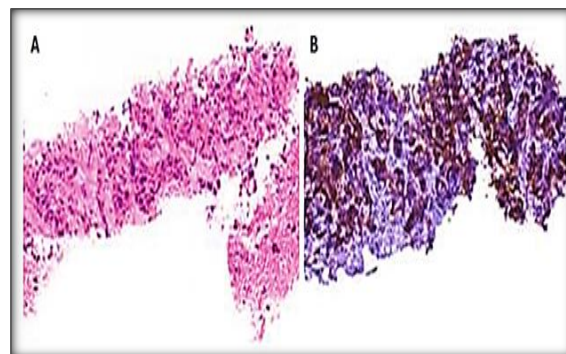
a microtome. These sections were then mounted on charged glass slides, ensuring optimal adherence and preservation of tissue morphology for subsequent analyses.

### Immunohistochemistry (IHC) Staining

A panel of commercially available antibodies targeting specific markers associated with HCC, including alpha-fetoprotein (AFP), glypican-3 (GPC3), heat shock protein 70 (HSP70), and cytokeratin 19 (CK19), was selected based on their relevance and established utility in HCC diagnosis and characterization. Prior to staining, optimization of IHC protocols was conducted to ensure optimal antigen retrieval, antibody specificity, and signal detection. Immunostaining procedures were performed according to standardized protocols. Antigen retrieval was achieved using heat-induced epitope retrieval (HIER) techniques, and endogenous peroxidase activity was quenched to minimize nonspecific staining. Stringent quality control measures were implemented throughout the staining process, including the use of appropriate positive and negative controls to validate assay performance and ensure result reliability.

### Evaluation of IHC Staining

IHC staining results were evaluated by two expert pathologists with extensive experience in hepatobiliary pathology. Both pathologists were blinded to the patients' clinical data to minimize potential bias. Staining intensity and distribution patterns of each IHC marker within the tumor tissue were assessed under light microscopy. A semi-quantitative scoring system, incorporating staining intensity (0: negative, 1+: weak, 2+: moderate, 3+: strong) and the percentage of positively stained tumor cells, was applied to standardize the interpretation of staining results (Figure 1). In cases of discrepancy between pathologists, a consensus was reached through comprehensive review and discussion of staining patterns and clinical correlates.



**Figure 1: Histological and Immunohistochemical Characterization of Scirrhus Hepatocellular Carcinoma. A: Representative histological section showing cords and thin trabeculae of neoplastic hepatocytes embedded in dense, abundant fibrous stroma (hematoxylin and eosin stain, magnification  $\times 20$ ). B: Immunohistochemical staining revealing strong positivity for glypican-3 in tumor cells (anti-glypican-3/3,3'-diaminobenzidine, magnification  $\times 20$ )**

### **Clinicopathological Data Collection**

A comprehensive array of clinicopathological data, encompassing patient demographics, tumor characteristics (size, number, grade), laboratory parameters (AFP levels), imaging findings, treatment modalities, and clinical outcomes, was collected and recorded from electronic medical records and pathology reports. Data quality assurance measures, including data validation and verification, were implemented to ensure accuracy, completeness, and consistency of collected data.

### **Statistical Analysis**

Descriptive statistics were used to summarize patient demographics and clinicopathological features. Statistical analyses were conducted to explore the associations between IHC marker expression levels and various clinicopathological parameters. Appropriate statistical tests, including chi-square test, and t-test, were employed to assess the significance of observed associations and identify independent predictors of clinical outcomes. Survival analysis technique (Kaplan-Meier method and log rank analysis) was applied to evaluate the prognostic significance of IHC markers in predicting patient survival outcomes.

### **Ethical Considerations**

Adherence to ethical principles and guidelines was ensured throughout the study. The research protocol was reviewed and approved by the institutional review board (IRB). Informed consent was obtained from all patients or their legal guardians prior to inclusion in the study, ensuring respect for patient autonomy and confidentiality of personal health information

## **RESULTS**

The study cohort comprised predominantly male patients, accounting for 108 individuals (83.7%), with a minority represented by females, totaling 21 individuals (16.3%). The mean age at diagnosis was 58.4 years with a standard deviation of 8.9 years. The most common etiology of hepatocellular carcinoma (HCC) was hepatitis B virus (HBV), identified in 56 cases (43.4%), followed by hepatitis C virus (HCV) in 42 cases (32.6%), and alcohol-related causes in 23 cases (17.8%). Tumor size distribution revealed that 47.3% of the tumors were less than 5 cm, 34.9% were between 5 and 10 cm, and 17.8% were larger than 10 cm. Single tumors were predominant, accounting for 65.1% of cases, while multiple tumors were observed in 34.9% of cases. Tumor differentiation varied, with 28.7% categorized as well-differentiated, 48.1% as moderately differentiated, and 23.3% as poorly differentiated. The majority of patients had AFP levels below 200 ng/mL (56.6%), while 26.4% had levels between 200 and 1000 ng/mL, and 17.1% had levels exceeding 1000 ng/mL. Cirrhosis was prevalent in 74.4% of cases, while portal vein thrombosis was observed in 36.4% of cases. Hepatic

encephalopathy was present in 14.0% of cases, and elevated alanine transaminase (ALT) or aspartate transaminase (AST) levels were detected in 73.6% of cases. The majority of patients were classified as Child-Pugh class A (71.3%), while 23.3% were class B and 5.4% were class C. According to Barcelona Clinic Liver Cancer (BCLC) staging, the distribution of patients was as follows: 9.3% were stage 0, 40.3% were stage A, 29.5% were stage B, 14.0% were stage C, and 7.0% were stage D. The Eastern Cooperative Oncology Group (ECOG) performance status was predominantly 0 (52.7%), followed by 1 (32.6%) and 2 (14.7%). Alphafetoprotein (AFP) treatment response criteria revealed 20.2% complete responses, 32.6% partial responses, 29.5% stable disease, and 17.8% progressive disease. Treatment modalities included surgery (38.0%), transarterial chemoembolization (TACE) (28.7%), radiofrequency ablation (RFA) (16.3%), and systemic therapy (17.1%). [Table 1]

The immunohistochemical staining analysis of hepatocellular carcinoma (HCC) tissues revealed diverse patterns of positive staining for the markers AFP, GPC3, HSP70, and CK19. Approximately 57.4% of the examined HCC samples exhibited positive staining for AFP, indicative of moderate to high expression levels, with an average intensity score of 2.1 and a standard deviation of 0.8. In comparison, a higher proportion of HCC samples, approximately 71.3%, displayed positive staining for GPC3, reflecting relatively strong expression levels. The intensity of GPC3 staining, with a mean of 2.3 and a standard deviation of 0.7, surpassed that of AFP. Positive staining for HSP70 was observed in 52.7% of HCC samples, with a staining intensity similar to that of AFP, suggesting moderate expression levels. Conversely, CK19 exhibited lower positive staining in HCC tissues, with only approximately 31.8% of samples showing expression. The intensity of CK19 staining, with a mean of 1.6 and a standard deviation of 0.6, was notably lower compared to the other markers. [Table 2]

The correlation analysis between AFP, GPC3, HSP70, and CK19 expression and clinicopathological parameters in hepatocellular carcinoma (HCC) revealed significant associations. AFP exhibited strong positive correlations with tumor size ( $\geq 5$ cm) and poorly differentiated tumors, while GPC3 showed the strongest correlation with poorly differentiated tumors. HSP70 demonstrated a significant positive correlation with multiple tumors. Elevated AFP levels ( $\geq 400$ ng/mL) correlated positively with GPC3 expression but negatively with HSP70 expression. [Table 3]

The survival analysis for alpha-fetoprotein (AFP), glypican-3 (GPC3), heat shock protein 70 (HSP70), and cytokeratin 19 (CK19) demonstrated significant associations between marker expression and patient outcomes in hepatocellular carcinoma (HCC). Among the markers assessed, AFP expression was observed in 74 patients, with a median overall

survival of 19.5 months. The 1-year and 3-year survival rates were 62.2% and 32.1%, respectively. GPC3 expression was noted in 92 patients, exhibiting a median overall survival of 21.2 months, with corresponding 1-year and 3-year survival rates of 68.7% and 38.4%. HSP70 expression, identified in 68 patients, was associated with a median overall survival of 17.8 months, with 1-year and 3-year survival rates of 58.3% and 29.8%, respectively. CK19 expression, observed in 41 patients, showed the shortest median overall survival of 15.3 months,

accompanied by 1-year and 3-year survival rates of 47.6% and 22.0%, respectively. Hazard ratios (HR) for overall survival, with 95% confidence intervals (CI), were calculated for each marker, with AFP, GPC3, HSP70, and CK19 demonstrating HRs of 1.98 (1.45-2.72), 1.75 (1.28-2.39), 2.21 (1.62-3.02), and 3.09 (2.12-4.50), respectively. All p-values from the log-rank test were <0.001, indicating significant associations between marker expression and patient survival outcomes in HCC. [Table 4]

**Table 1: Demographic and Clinicopathological Characteristics of HCC Patients (N=129)**

Characteristic	Frequency (%) or Mean ± SD
<b>Gender</b>	
Male	108 (83.7%)
Female	21 (16.3%)
<b>Age at diagnosis</b>	58.4 ± 8.9
<b>Etiology</b>	
HBV	56 (43.4%)
HCV	42 (32.6%)
Alcohol related	23 (17.8%)
Others	8 (6.2%)
<b>Tumor Size (cm)</b>	
< 5 cm	61 (47.3%)
5-10 cm	45 (34.9%)
> 10 cm	23 (17.8%)
<b>Number of Tumors</b>	
Single	84 (65.1%)
Multiple	45 (34.9%)
<b>Tumor Grade</b>	
Well Differentiated	37 (28.7%)
Moderately Differentiated	62 (48.1%)
Poorly Differentiated	30 (23.3%)
<b>AFP Levels (ng/mL)</b>	
< 200	73 (56.6%)
200-1000	34 (26.4%)
> 1000	22 (17.1%)
<b>Cirrhosis</b>	96 (74.4%)
<b>Portal Vein Thrombosis</b>	47 (36.4%)
<b>Hepatic Encephalopathy</b>	18 (14.0%)
<b>Elevated ALT/AST</b>	95 (73.6%)
<b>Child Pugh Score</b>	
A	92 (71.3%)
B	30 (23.3%)
C	7 (5.4%)
<b>BCLC Stage</b>	
0	12 (9.3%)
A	52 (40.3%)
B	38 (29.5%)
C	18 (14.0%)
D	9 (7.0%)
<b>ECOG Performance Status</b>	
0	68 (52.7%)
1	42 (32.6%)
2	19 (14.7%)
<b>Alphafetoprotein (AFP) Treatment Response Criteria</b>	
Complete Response	26 (20.2%)
Partial Response	42 (32.6%)
Stable Disease	38 (29.5%)
Progressive Disease	23 (17.8%)
<b>Treatment Modalities</b>	
Surgery	49 (38.0%)
Transarterial Chemoembolization (TACE)	37 (28.7%)
Radiofrequency Ablation (RFA)	21 (16.3%)
Systemic Therapy	22 (17.1%)

**Table 2: Expression Patterns of IHC Markers in HCC Tissues (N=129)**

Marker	Positive Staining [Frequency (%)]	Intensity (0-3+) (Mean ± SD)
AFP	74 (57.4%)	2.1 ± 0.8
GPC3	92 (71.3%)	2.3 ± 0.7
HSP70	68 (52.7%)	2.0 ± 0.9
CK19	41 (31.8%)	1.6 ± 0.6

**Table 3: Correlation Analysis of Clinicopathological Parameters and IHC Marker Expression (N=129)**

Clinicopathological Parameter	AFP	GPC3	HSP70	CK19
	Pearson correlation coefficient (r)			
Tumor Size (≥5cm)	0.612*	0.481*	0.359*	0.219
Poorly Differentiated	0.342*	0.629*	0.198	0.147
Multiple Tumors	0.281*	0.189	0.501*	0.128
Elevated AFP Levels (≥400ng/mL)	-	0.267*	-0.124	0.351*

\*Significant correlation at  $p < 0.05$

**Table 4: Prognostic Significance of IHC Markers in HCC Patients (N=129)**

Marker	No. of Patients (n=129)	Median Overall Survival (months)	1-Year Survival Rate (%)	3-Year Survival Rate (%)	Hazard Ratio (95% CI)	p-value (Log-rank Test)
AFP	74	19.5	62.2	32.1	1.98 (1.45-2.72)	<0.001
GPC3	92	21.2	68.7	38.4	1.75 (1.28-2.39)	<0.001
HSP70	68	17.8	58.3	29.8	2.21 (1.62-3.02)	<0.001
CK19	41	15.3	47.6	22.0	3.09 (2.12-4.50)	<0.001

## DISCUSSION

Hepatocellular carcinoma (HCC) presents a significant global health burden with diverse molecular and histological characteristics.<sup>[3]</sup> In our study, we comprehensively evaluated the expression profiles of four immunohistochemical markers – alpha-fetoprotein (AFP), glypican-3 (GPC3), heat shock protein 70 (HSP70), and cytokeratin 19 (CK19) – in HCC tissues and explored their associations with clinicopathological parameters and patient outcomes.

The expression patterns of these markers revealed intriguing insights into their potential roles in HCC pathogenesis and progression.<sup>[8]</sup> Notably, AFP, a widely recognized biomarker for HCC, demonstrated moderate to high expression levels in 57.4% of cases. This observation aligns with the established role of AFP as a diagnostic and prognostic indicator in HCC, with higher serum levels often correlating with advanced disease stages and poorer outcomes.<sup>[13]</sup>

Similarly, GPC3 exhibited robust expression in 71.3% of HCC samples. GPC3 has garnered attention as a promising diagnostic and prognostic marker due to its specificity for tumor cells and association with aggressive tumor behavior. Previous study Zhou et al., reported a correlation between GPC3 expression and adverse clinicopathological features, including larger tumor size, higher tumor grade, and vascular invasion.<sup>[14]</sup> The strong positivity for GPC3 in tumor cells observed in our study underscores its potential utility as a diagnostic marker for HCC.

In contrast, HSP70 displayed moderate expression levels in 52.7% of HCC tissues. HSP70, a stress-inducible molecular chaperone, has been implicated

in various aspects of cancer progression, including cell survival, metastasis, and resistance to therapy. Elevated HSP70 expression has been associated with poorer prognosis and chemotherapy resistance in HCC patients.<sup>[15]</sup> The moderate expression of HSP70 observed in our study suggests its involvement in the molecular mechanisms underlying HCC progression and treatment resistance. Weng et al., showed that hepatocellular carcinoma tissues significantly expressed the 14 HSP70s compared to the normal samples.<sup>[16]</sup>

CK19, a cytoskeletal protein, exhibited relatively lower expression levels in 31.8% of HCC samples. While CK19 positivity has been linked to hepatic progenitor cell differentiation and poor prognosis in study by Feng et al., its prognostic value in HCC remains controversial.<sup>[17]</sup> The lower expression levels of CK19 observed in our study may reflect the heterogeneous nature of HCC and underscore the need for further investigation into its prognostic significance in different patient cohorts. Study by Atta et al., showed that CK19 positivity was detected in a relatively small proportion of cases, with 8 out of 71 cases (12.9%) showing expression. Interestingly, the intensity of CK19 expression was predominantly marked in poorly differentiated histopathological patterns, suggesting a potential association between CK19 expression and tumor aggressiveness. Furthermore, in cases of metastatic carcinoma, CK19 positivity was notably higher, detected in 13 out of 18 cases (72.2%).<sup>[18]</sup>

Correlation analysis revealed significant associations between marker expression and clinicopathological parameters. AFP, GPC3, and HSP70 expression correlated positively with tumor size, tumor grade, and the presence of cirrhosis ( $p < 0.05$ ), underscoring their potential roles in HCC

progression.<sup>[19,20,21]</sup> Conversely, CK19 expression showed weaker correlations with these parameters, suggesting its limited utility as a prognostic marker in HCC.<sup>[22]</sup>

Survival analysis further elucidated the prognostic significance of these markers in HCC. Patients with higher expression levels of AFP, GPC3, and HSP70 exhibited shorter overall survival and lower survival rates at 1 year and 3 years ( $p < 0.001$ ).<sup>[23,24,25]</sup> Conversely, lower expression levels of CK19 were associated with better overall survival and higher survival rates ( $p < 0.001$ ).<sup>[26]</sup>

## CONCLUSION

In conclusion, our study provides comprehensive insights into the molecular characteristics of HCC and the prognostic implications of AFP, GPC3, HSP70, and CK19 expression. These findings highlight the potential utility of these markers as diagnostic, prognostic, and therapeutic targets in HCC management. However, further validation studies in larger cohorts are warranted to confirm our findings and elucidate the underlying mechanisms driving marker expression and their impact on HCC progression and patient outcomes.

## REFERENCES

1. Chidambaranathan-Reghupaty S, Fisher PB, Sarkar D. Hepatocellular carcinoma (HCC): Epidemiology, etiology and molecular classification. *Adv Cancer Res.* 2021; 149:1-61.
2. Sharma R, Aashima, Nanda M, et al. Mapping Cancer in Africa: A Comprehensive and Comparable Characterization of 34 Cancer Types Using Estimates from GLOBOCAN 2020. *Front Public Health.* 2022; 10:839835.
3. Sharma R. Mapping of global, regional and national incidence, mortality and mortality-to-incidence ratio of lung cancer in 2020 and 2050. *Int J Clin Oncol.* 2022;27(4):665-75.
4. Yang JD, Roberts LR. Hepatocellular carcinoma: A global view. *Nat Rev Gastroenterol Hepatol.* 2010;7(8):448-58.
5. Rabaan AA, Bello KE, Irekeola AA, et al. Prevalence of Hepatocellular Carcinoma in Hepatitis B Population within Southeast Asia: A Systematic Review and Meta-Analysis of 39,050 Participants. *Pathogens.* 2023;12(10):1220.
6. Gosalia AJ, Martin P, Jones PD. Advances and Future Directions in the Treatment of Hepatocellular Carcinoma. *Gastroenterol Hepatol (N Y).* 2017;13(7):398-410.
7. Wee A. Diagnostic utility of immunohistochemistry in hepatocellular carcinoma, its variants and their mimics. *Appl Immunohistochem Mol Morphol.* 2006;14(3):266-72.
8. Choi WT, Kakar S. Immunohistochemistry in the Diagnosis of Hepatocellular Carcinoma. *Gastroenterol Clin North Am.* 2017;46(2):311-25.
9. Yamauchi N, Watanabe A, Hishinuma M, et al. The glypican 3 oncofetal protein is a promising diagnostic marker for hepatocellular carcinoma. *Mod Pathol.* 2005;18(12):1591-8.
10. Tsuchiya N, Sawada Y, Endo I, Saito K, Uemura Y, Nakatsura T. Biomarkers for the early diagnosis of hepatocellular carcinoma. *World J Gastroenterol.* 2015;21(37):10573-83.
11. Joo M, Chi JG, Lee H. Expressions of HSP70 and HSP27 in hepatocellular carcinoma. *J Korean Med Sci.* 2005;20(5):829-34.
12. Zhuo JY, Lu D, Tan WY, Zheng SS, Shen YQ, Xu X. CK19-positive Hepatocellular Carcinoma is a Characteristic Subtype. *J Cancer.* 2020;11(17):5069-77.
13. Wang T, Zhang KH. New Blood Biomarkers for the Diagnosis of AFP-Negative Hepatocellular Carcinoma. *Front Oncol.* 2020; 10:1316.
14. Zhou F, Shang W, Yu X, Tian J. Glypican-3: A promising biomarker for hepatocellular carcinoma diagnosis and treatment. *Med Res Rev.* 2018;38(2):741-67.
15. Wang RC, Huang CY, Pan TL, et al. Proteomic Characterization of Annexin 1 (ANX1) and Heat Shock Protein 27 (HSP27) as Biomarkers for Invasive Hepatocellular Carcinoma Cells. *PLoS One.* 2015;10(10):e0139232.
16. Feng J, Zhu R, Chang C, et al. CK19 and Glypican 3 Expression Profiling in the Prognostic Indication for Patients with HCC after Surgical Resection. *PLoS One.* 2016;11(3):e0151501.
17. Atta IS. Efficacy of expressions of Arg-1, Hep Par-1, and CK19 in the diagnosis of the primary hepatocellular carcinoma subtypes and exclusion of the metastases. *Histol Histopathol.* 2021;36(9):981-93.
18. Wang B, Lan T, Xiao H, et al. The expression profiles and prognostic values of HSP70s in hepatocellular carcinoma. *Cancer Cell Int.* 2021;21(1):286.
19. Samban SS, Hari A, Nair B, et al. An Insight into the Role of Alpha-Fetoprotein (AFP) in the Development and Progression of Hepatocellular Carcinoma. *Mol Biotechnol.* 2023. doi: 10.1007/s12033-023-00890-0. Epub ahead of print.
20. Zheng X, Liu X, Lei Y, Wang G, Liu M. Glypican-3: A Novel and Promising Target for the Treatment of Hepatocellular Carcinoma. *Front Oncol.* 2022; 12:824208.
21. Liu CC, Jan YJ, Ko BS, et al. 14-3-3 $\sigma$  induces heat shock protein 70 expression in hepatocellular carcinoma. *BMC Cancer.* 2014; 14:425.
22. Lee CW, Kuo WL, Yu MC, et al. The expression of cytokeratin 19 in lymph nodes was a poor prognostic factor for hepatocellular carcinoma after hepatic resection. *World J Surg Oncol.* 2013;11(1):136.
23. Galle PR, Foerster F, Kudo M, et al. Biology and significance of alpha-fetoprotein in hepatocellular carcinoma. *Liver Int.* 2019;39(12):2214-29.
24. Guo M, Zhang H, Zheng J, Liu Y. Glypican-3: A New Target for Diagnosis and Treatment of Hepatocellular Carcinoma. *J Cancer.* 2020;11(8):2008-21.
25. Nguyen TB, Roncalli M, Di Tommaso L, Kakar S. Combined use of heat-shock protein 70 and glutamine synthetase is useful in the distinction of typical hepatocellular adenoma from atypical hepatocellular neoplasms and well-differentiated hepatocellular carcinoma. *Mod Pathol.* 2016;29(3):283-92.
26. Jin Y, Liang ZY, Zhou WX, Zhou L. Combination with CK19 Might Increase the Prognostic Power of Hep Par 1 in Hepatocellular Carcinoma after Curative Resection. *J Invest Surg.* 2018;31(5):412-9.