

Original Research Article

CORRELATION BETWEEN DIABETIC FOOT ULCER GRADE AND OCT-MEASURED VOLUME OF MACULA AND NEURORETINAL RIM AREA, IN A TERTIARY HEALTH CARE CENTER OF NORTHERN KARNATAKA.

Machavaram Amala Krishna¹, Raghavendra K. Ijeri², Manjunath S. Kotennavar³

¹Postgraduate, Department of Ophthalmology, Shri B M Patil Medical College & Research Centre, Vijayapura, Karnataka, India.

²Associate Professor, Department of Ophthalmology, Shri B M Patil Medical College & Research Centre, Vijayapura, Karnataka, India.

³Professor &HOD, Department of General Surgery, Shri B M Patil Medical College & Research Centre, Vijayapura, Karnataka, India.

Received : 07/02/2024
Received in revised form : 05/04/2024
Accepted : 22/04/2024

Corresponding Author:

Dr. Machavaram Amala Krishna
Postgraduate, Department of
Ophthalmology, Shri B M Patil
Medical College & Research Centre,
Vijayapura, Karnataka, India.

Email: amalakrishna002@gmail.com

DOI: 10.5530/ijmedph.2024.2.75

Source of Support: Nil,
Conflict of Interest: None declared

Int J Med Pub Health
2024; 14 (2); 383-386

ABSTRACT

Background: To study the correlation between the grade of Diabetic Foot Ulcer (DFU) and Optical Coherence Tomography(OCT)-measured volume of macular subfield and neuroretinal rim area in patients attending a tertiary health care center of northern Karnataka.

Materials and Methods: A cross-sectional study was carried out on the right eyes of 117 subjects with various grades of DFU consulting a tertiary health care centre of northern Karnataka from August 2022 to August 2023. A detailed history was taken, including demographics. DFU grading was done using the standard Wagner's classification system of diabetic foot ulcers¹. Patients with a previous history of treatment for diabetic retinopathy (DR), like laser photocoagulations and intravitreal anti-VEGF injections, are excluded from the study.

Results: The mean age of the patients was 55.63+/- 12.820 years. There were 80 males (68.4%) and 37 females (31.6%). SPSS software version 20 was used to present descriptive statistics for categorical parameters using frequency and percentage. Mean and standard deviation were used for continuous parametric data. Means of different groups were compared using the ANOVA (Analysis of Variance) test. P value< 0.05 was considered statistically significant. P< 0.001 was considered highly statistically significant. Comparison of DFU grade with the OCT-measured volume of the macula (mm³) and neuroretinal rim area (mm²) showed a strong positive correlation with a P value< 0.001 and< 0.05, respectively, which are statistically significant.

Conclusion: Our study reports a highly statistically significant correlation between the grades of DFU with the volume of the macula and neuroretinal rim area in all the subjects, thus concluding that patients with DFU have a higher risk of diabetic maculopathy and vice-versa, highlighting the significance of regular screening for both DFU and diabetic maculopathy to prevent serious adverse outcomes of DM.

Keywords: Diabetes, Diabetic Foot Ulcer, Maculopathy, neuroretinal rim area.

INTRODUCTION

Diabetes Mellitus (DM) is a metabolic dysregulation characterized by chronic high blood sugars and disturbances chiefly in carbohydrate metabolism associated with relative or absolute deficiencies in insulin secretion or its action.^[2,3]

DM is a major global public health problem. The International Diabetes Federation (IDF) stated that there have already been 463 million adults worldwide with DM since 2019, and this number is expected to continue to rise in the coming years.^[4,5] It is estimated that by 2045, the global prevalence of DM will reach 9.9%, approximately 770 million people.^[4,5]

The metabolic dysregulation in DM causes secondary pathological changes in multiple organ systems, imposing a tremendous burden on the individual with diabetes. Its harmful effects on various organ systems like the eye, renal system and nervous system result in complications like diabetic retinopathy, nephropathy and neuropathy by microangiopathy.^[6,3] Diabetic foot ulcer (DFU) refers to foot infection, ulceration and profound tissue destruction caused by peripheral neuropathy and varying degrees of vascular disease in patients with diabetes. It is one of the leading causes of frailty and mortality in patients with DM. It has become a significant public health problem that burdens patients and society tremendously.^[7]

DR is the most frequent microvascular ocular complication of diabetes. The detection of DR is related to the appearance of multiple primary and secondary symptoms. Without the patient's full awareness, the disease will cause more damage to the retinal vessels, causing deflection to the eyes and leading, in some cases, to total loss of sight.^[8]

Optical Coherence Tomography (OCT)

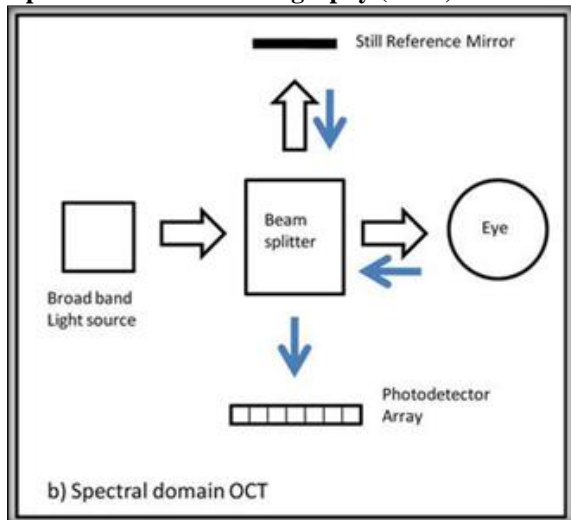


Image source^[9]

Figure 1: Mechanism of functioning of SD-OCT

Spectral Domain-OCT (SD-OCT) uses a photodetector array to capture the depth scan without moving the reference mirror. Therefore, only a lateral scan has to be performed.^[10] This increases the scan speed enormously. Further technology refinement led to changing the near-infrared broadband superluminescent diode light source of 840 nm wavelength in SD-OCT to a tunable laser source with a center of 1050 nm wavelength.^[11]

Aims and Objectives of the Study

The goal of this study was to compare and analyze the grade of Diabetic Foot Ulcer (DFU) with OCT-measured volume of the macular subfield (mm³) and neuroretinal rim area (mm²).

MATERIAL AND METHODS

A cross-sectional study was carried out in a tertiary health care center in northern Karnataka from August 2022 to August 2023. One hundred seventeen people with DFU attending the center's General Surgery and Ophthalmology departments were enrolled in the study. Institutional ethical clearance was obtained for the study. Informed and written consent was taken from all the study participants. The right eyes of the study subjects were included. The inclusion criteria were subjects with various grades of DFU. The exclusion criteria were foot ulcers of nondiabetic etiology and previous treatment for DR with laser photocoagulations or intravitreal injections. A detailed history was obtained from all the patients. The grading of DFU was done using the Wagner system of classification of diabetic foot ulcers. The volume of the macula and area of the neuroretinal rim was measured using Spectral Domain-Optical Coherence Tomography (MODEL 500, CIRRUS HD, ZEISS).

Wagner's classification of diabetic foot ulcers.^[1]

Table 1: Wagner's system of classification of DFUs

Wagner's Classification	
Grade 0	Skin intact, but bony deformities lead to "foot at risk."
Grade 1	Superficial ulcer
Grade 2	Deeper, full-thickness extension
Grade 3	Deep abscess formation or osteomyelitis
Grade 4	Partial Gangrene of forefoot
Grade 5	Extensive Gangrene

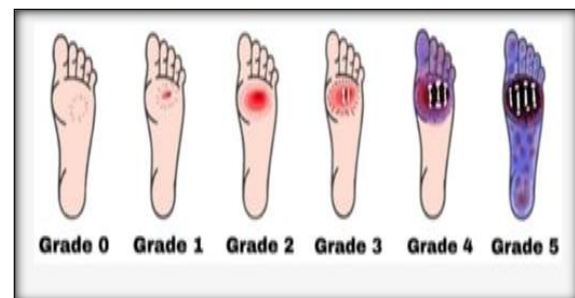


Image source^[12]

Figure 2: Pictorial representation of Wagner's system of classification of DFUs

RESULTS

Table 2: The mean age of all subjects represented in Mean \pm Standard deviation. The mean age of subjects was 55.63 \pm 12.820. [Table 2]

Among the subjects, 80 (68.4%) were males and 37 (31.6%) were females. The gender-wise distribution showed a preponderance for male sex. [Table 3]

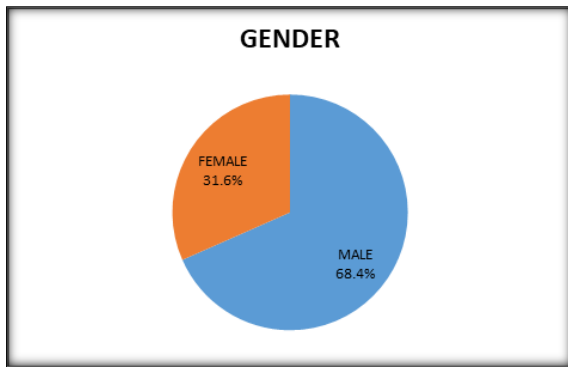


Figure 3: Pie chart showing gender distribution among study subjects

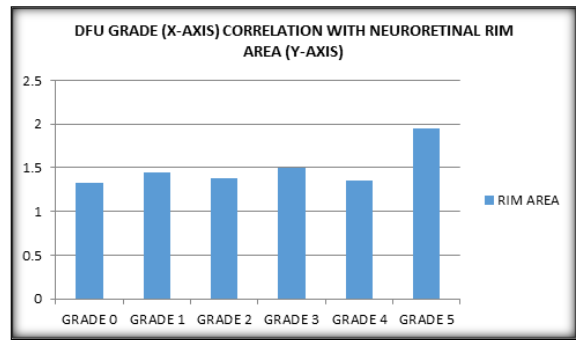


Figure 5: Bar graph depicting the relation between neuroretinal rim area with the grade of DFU. Results were found to be statistically significant ($P < 0.05$)

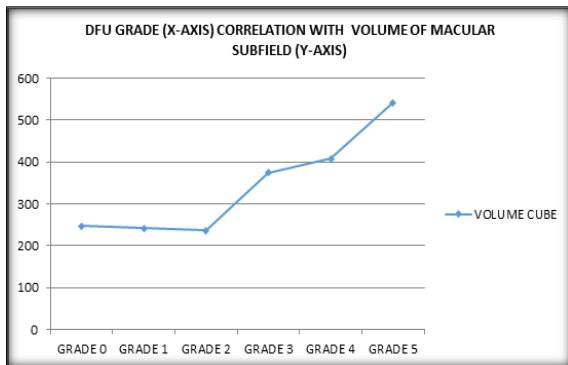


Figure 4: Line graph depicting the relation between the volume of macula (mm³) with the grade of DFU. Results are highly statistically significant ($P < 0.001$).



Figure 6: Right eye SD-OCT central macular subfield scan showing increased thickness, volume, cystic spaces, hard exudates, back shadowing in a 69-year-old male with Grade IV DFU

Mean Age of Subjects

Table 2: The mean age of all subjects represented in Mean \pm Standard deviation.

The mean age of subjects was 55.63 \pm 12.820

AGE	Mean	Std. Deviation	Minimum	maximum
	55.63	12.820	18	85

Gender Distribution

Table 3: Frequency distribution of gender among all study subjects.

GENDER	Frequency	Percent
MALE	80	68.4
FEMALE	37	31.6
TOTAL	117	100.0

DFU Grade correlation with volume of macula(MM³)

Table 4: Correlation between volume of macula (mm³) and the grade of DFU. Test used- ANOVA, $P < 0.001$ highly statistically significant

ILM-RPE VOLUME CUBE (MM ³)	DFU GRADE (Wagner's)	MEAN	SD	F VALUE	PVALUE
RIGHT EYES	GRADE 0	9.683	.7826	4.998	<0.001
	GRADE 1	9.956	.6817		
	GRADE 2	10.076	.9216		
	GRADE 3	10.338	1.5315		
	GRADE 4	10.054	1.2170		
	GRADE 5	11.470	1.4260		

DFU Grade correlation with neuroretinal rim area(MM²)

Table 5: Correlation between neuroretinal rim area (mm²) and the DFU grade. Test used- ANOVA, $P < 0.05$ statistically significant

RIM AREA (MM ²)	DFU GRADE (Wagner's)	MEAN	SD	F VALUE	PVALUE
RIGHT EYES	GRADE 0	1.3317	.33160	2.897	.014
	GRADE 1	1.4491	.46770		
	GRADE 2	1.3835	.36932		
	GRADE 3	1.4975	.39158		

	GRADE 4	1.3577	.33370		
	GRADE 5	1.9520	.66530		

DISCUSSION

DR is one of the most common ocular complications of diabetes, causing severe visual morbidity, sometimes leading to total loss of vision.^[13] DFU is a peripheral neuropathic and microangiopathic cause of physical incapacity, at times, needing amputation of lower extremity in severe cases. These two consequences of DM are often synergistic and, if not well managed, can adversely impact disease prognosis and considerably drive healthcare costs. In the present study, people with DFU attending the Ophthalmology and General Surgery departments in a tertiary health care center of northern Karnataka from August 2022 to August 2023 were enrolled and studied for the presentation of Diabetic maculopathy. A total of 117 patients with DFU were considered for the study. The right eyes of the subjects were included in the study. The predominant average age group affected with diabetic retinopathy was 55.63 years. The gender-wise distribution showed a preponderance for the male sex. In the present study, 80 (68.4%) were males and 37 (31.6%) were females. A similar male predominance was reported by Dandona et al., 1999,^[14] and Kohner et al., 1998.^[15] In the present study, the volume of the macular subfield and neuroretinal rim area were correlated to DFU severity. Macular volume changes (mm³) positively correlated with the grade of DFU, which was highly statistically significant with a P value < 0.001 (Table 4, Figure 4). Also, neuroretinal rim area (mm²) correlated positively with the grade of DFU, with a statistically significant P value < 0.05 (Table 5, Figure 5). Thus, the above findings show a high risk of diabetic maculopathy among the study patients of DFU.

Numerous biochemical pathways have been proposed as potential links between hyperglycemia and diabetic maculopathy, including increased polyol pathway flux, activation of diacylglycerol (DAG), Protein Kinase C pathway, increased expression of growth factors, hemodynamic changes, excessive production of advanced glycation end products (AGEs), free radical stress, activation of the renin-angiotensin-aldosterone system (RAAS), subclinical inflammation and leukostasis.

Thus, the present study highlights the significance of regular screening, early diagnosis, and treatment for these two debilitating consequences of DM in preventing progression to further irreversible stages.

CONCLUSION

In the present study, most of the patients had increased volume of macular subfield (mm³) and increased neuroretinal rim area (mm²), which

positively correlated with the grade of DFU (Table 4-5, Figure 4-5). Early diagnosis of maculopathy and its early treatment initiation reduces significant visual loss by controlling the progression of maculopathy. This study highlights the significance of regular screening of all DFU patients for early initiation of treatment to prevent significant ocular morbidity. Also, it is equally important to refer all DR and diabetic maculopathy patients to DFU clinics to screen for early manifestations of DFU by neurovascular assessments of the foot to prevent serious adverse outcomes of DFU, like amputations. However, further studies are required to validate the conclusions of the present study.

REFERENCES

- Shah P, Inturi R, Anne D, Jadhav D, Viswambharan V, Khadilkar R, Dnyanmote A, Shahi S. Wagner's Classification as a Tool for Treating Diabetic Foot Ulcers: Our Observations at a Suburban Teaching Hospital. *Cureus*. 2022 Jan 22;14(1): e21501.
- Nanditha A, et al. Diabetes in Asia and the Pacific: Implications for the Global Epidemic. *Diabetes Care*. 2016;39(3):472-485.
- Anithaa, E. "Clinical Study on Diabetic Retinopathy and Its Management." 2008.
- Guariguata L, Whiting DR, Hambleton I, Beagley J, Linnenkamp U, Shaw JE. Global estimates of diabetes prevalence for 2013 and projections for 2035. *Diabetes Res Clin Pract*. 2014;103(2):137-149.
- Cho NH, Shaw J, Karuranga S, et al. IDF diabetes atlas: global estimates of diabetes prevalence for 2017 and projections for 2045. *Diabetes Res Clin Pract*. 2018; 138:271-281.
- Vangeepuram N, Liu B, Chiu PH, Wang L, Pandey G. Predicting youth diabetes risk using NHANES data and machine learning. *Sci Rep*. 2021;11(1):11212.
- Jia Z, Liu L, Zhang S, et al. Proteomics changes after negative pressure wound therapy in diabetic foot ulcers. *Mol Med Rep*. 2021;24(6):834.
- Ibrahim A. IDF Clinical Practice Recommendation on the Diabetic Foot: A Guide for Healthcare Professionals. Vol 127. Elsevier; 2017:285-287.
- Ruia S, Tripathy K. Optical Coherence Tomography in Diabetic Retinopathy [Internet]. *Diabetic Eye Disease - From Therapeutic Pipeline to the Real World*. IntechOpen; 2022.
- Aumann S, Donner S, Fischer J, et al. Optical coherence tomography (OCT): Principle and technical realization. *High Resolution Imaging in Microscopy and Ophthalmology*. 2019:59-85.
- Chinn SR, Swanson EA, Fujimoto JG. Optical coherence tomography using a frequency-tunable optical source. *Optics letters*. 1997 Mar 1;22(5):340-342.
- Ansari P, Akther S, Khan JT, Islam SS, Masud MSR, Rahman A, Seidel V, Abdel-Wahab YHA. Hyperglycaemia-Linked Diabetic Foot Complications and Their Management Using Conventional and Alternative Therapies. *Applied Sciences*. 2022; 12(22):11777.
- Serban D, Papanas N, Dascalu AM, et al. Diabetic Retinopathy in Patients with Diabetic Foot Ulcer: A Systematic Review. *The International Journal of Lower Extremity Wounds*. 2021;20(2):98-103.
- Dandona L, Dandona R, Naduvillath JJ, Mc Carty CA, Rao GN. Population based assessment of diabetic retinopathy in an urban population in Southern India *Br J Ophthalmol* 1999;83:937-940.
- Kohner EM, Aldington SJ, Stralton IM et al. Diabetic retinopathy at diagnosis of NIDDM and associated risk factors. United Kingdom Prospective Diabetic Retinopathy Study 30. *Arch Ophthalmol* 1998;116:297-353.